



PRESENTING CLINICAL SIGNS

DATE History: Grade 2/6 murmur. Collapsing last night and was open mouth breathing. Diabetic. BG last night was 175.

7/11/23

ECHOCARDIOGRAPHIC FINDINGS

2D, M-mode, and Doppler study.

PERFORMED BY:

Sara Hansen

Left atrial size is normal. The mitral valve is normal. Left ventricular wall thickness is normal. Left ventricular internal dimensions are normal. Left ventricular systolic function is normal. The aorta and aortic valve are normal. Right atrial and right ventricular dimensions are normal. The tricuspid valve is normal. The pulmonary artery and pulmonic valve are normal. No shunting lesions are visualized. No pericardial effusion or cardiac masses are seen.

INTERPRETED BY

Keith Blass, DVM,
MS, DACVIM
(Cardiology)

LA/Ao - 1.29
IVSd - 4.4 mm
LVPWd - 4.5 mm
LVIDd - 17.0 mm
LVIDs - 7.0 mm
FS - 58.8%
LVOT - 0.50 m/s
RVOT - 0.80 m/s

PATIENT

Martin Ciattei

SPECIES ASSESSMENT/RECOMMENDATIONS

Normal echocardiogram

Feline

This examination demonstrates no evidence of structural heart disease. While a definitive reason for Martin's murmur was not identified, it's likely that his murmur is functional/innocent in nature, as no flow abnormalities that could result in the development of a pathologic murmur were appreciated in the image set.

BREED

DLH

Given the absence of abnormalities, no reason for Martin's collapsing episode or open mouth breathing is appreciated in the image set.

SEX

No therapy is recommended based on this exam.

MN

A recheck echocardiogram is recommended if the characteristics of Martin's murmur change, or if other new physical exam and/or clinical abnormalities suggestive of cardiac dysfunction develop.

AGE

16 y

WEIGHT

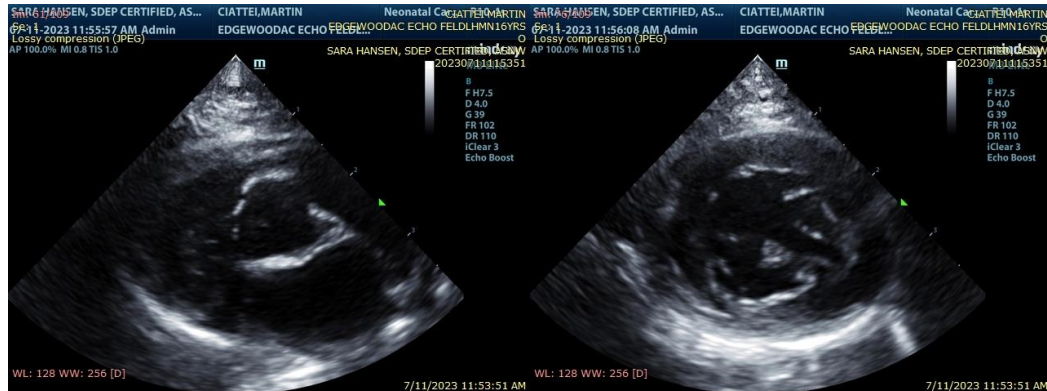
10.9 lb

HOSPITAL NAME

Edgewood AC

REFERRING VET

Dr. Kimball





DATE The information and recommendations provided are based on the images presented by the referring veterinarian. No evaluation can be communicated regarding pathology that was not visible in the image/video clips provided.

7/11/23

Thank you for this referral. If the clinical or image interpretation does not parallel your findings or if I can be of any further assistance please contact me.

PERFORMED BY:

Sara Hansen

Keith Blass, DVM, MS, DACVIM (Cardiology)

INTERPRETED BY

KeithBlass@gmail.com
631-804-5754

Keith Blass, DVM,
MS, DACVIM
(Cardiology)

PATIENT

Martin Ciattei

SPECIES

Feline

BREED

DLH

SEX

MN

AGE

16 y

WEIGHT

10.9 lb

HOSPITAL NAME

Edgewood AC

REFERRING VET

Dr. Kimball